The Treatment of Traumatic Posterior Sternoclavicular Joint Injuries

Michael A. Wirth, M.D. • Gordon I. Groh, M.D. • Charles A. Rockwood Jr., M.D.
Investigation performed at University of Texas Medical Center at San Antonio, Department of Orthopedics
Corresponding author: Gordon I. Groh M.D. • 828 258 8800 • ggroh@brbj.com

ABSTRACT

BACKGROUND: Traumatic posterior sternoclavicular joint injuries are rare. However, complications associated with this entity are common and include brachial plexus compression, pneumothorax, vascular compromise, esophageal rupture, and death. Although many of these complications are observed at the time of injury, late appearing complications have also been noted with unreduced retrosternal injuries, and highlight the importance of decompressing the hilar structures by closed or open reduction techniques.

METHODS: Between 1976 and 1993, 34 patients with a traumatic posterior sternoclavicular joint injury were treated at our institution. Eight of these patients were treated for displaced physeal fractures of the medial clavicle, and excluded from the study. Of the remaining 26 patients, one died and four were lost to follow-up, leaving 21 posterior sternoclavicular dislocations for long-term follow-up (average, five years). Signs and symptoms of posterior dislocation of the sternoclavicular joint included dysphagia, ipsililateral extremity cyanosis and swelling, parasthesia, dyspnea and shortness of breath. Associated injuries included pulmonary and cardiac contusion, pneumothorax, subclavian artery and vein injury and associated fractures. All patients underwent a trial of closed reduction. Closed reduction was successful in eight patients (Group I). The remaining 13 patients were treated with open reduction and sternoclavicular joint reconstruction (Group II).

RESULTS: Patients were evaluated with respect to pain, function, range of motion, strength, and patient satisfaction, according to a modification of the University of California at Los Angeles Rating Scale. Overall, 18 of the 21 patients were graded as good or excellent. Patients, treated with either closed or open reduction, compared favorably in terms of improvement in ratings for pain, strength, motion, and the ability to perform work and sports.

CONCLUSION: Our experience suggests that closed reduction compares favorably with open reduction. 38% of patients evaluated, required only closed reduction as their definitive treatment. Moreover, once the joint has been reduced closed, it is usually stable. In the present series, early recognition of injury followed by closed reduction and figure-of-eight immobilization was highly successful, and obviated the risks of operation. Patients who failed closed reduction, obtained good results with operative treatment aimed at reconstruction of the costoclavicular ligaments.

INTRODUCTION

Sternoclavicular joint injuries have been classified on the basis of anatomy and etiology, with traumatic posterior dislocation and posteriorly displaced physeal fracture of the medial clavicle being the least common types of injuries. (7, 33-35) The serious complications that occur with sternoclavicular joint trauma are primarily limited to those posterior injuries and include brachial plexus compression, (19,23) pneumothorax and respiratory distress, (12,29) vascular compromise, (Figure 1) (14, 18, 25,29) dysphagia and hoarseness, (Figure 2) (1,12,20,24,26) and death. (17,20,41). Worman and Leagus, in a review of the complications associated with posterior sternoclavicular joint injuries, reported that sixteen of sixty patients reviewed from the literature had suffered complications of the trachea, esophagus, or great vessels. (46) Although the majority of these complications are observed at the time of injury, late appearing complications have also been noted with unreduced retrosternal injuries and include thoracic outlet syndrome and brachial plexopathy, (13,32) subclavian artery compression, (2) exertional dyspnea, (47) and fatal sepsis following the development of a tracheoesophageal fistula (41)

The serious nature of these injuries and the frequency of associated complications emphasize the importance of careful evaluation and management. The purpose of our report is to review the results of treatment in two groups of patients with traumatic posterior sternoclavicular joint injuries. The first group of patients (Group I) was treated with closed reduction, while the second group (Group II) was managed with open reduction and reconstruction of the costoclavicular ligaments.

FIGURE 1

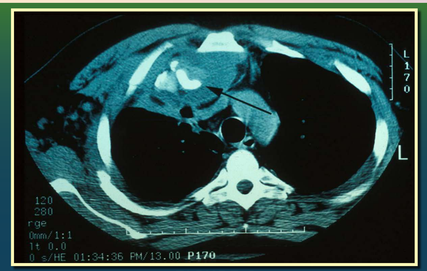

FIGURE 2

METHODS

Between 1976 and 1993, 34 patients with a traumatic posterior sternoclavicular were joint injury were treated by the two senior authors at our institution. Eight of these patients were diagnosed with a displaced physeal fracture of the medial clavicle and excluded. Of the remaining 26 patients, one died and four were lost to follow-up, leaving twenty-one patients available for evaluation. Medical records, follow-up clinical visits, radiographic studies, questionnaires, telephone calls, and consultation reports with referring physicians were reviewed.

There were seventeen men and four women. The avenge age at the time of treatment was thirty years (range, twenty-four to fifty-four years). The patients were divided into two groups based upon whether they had received closed reduction, or open reduction as their definitive treatment.

GROUP I (CLOSED REDUCTION)

Group I consisted of eight patients, six male and two female, with an average age of thirty-nine years (range, twenty-five to fifty-four). The injuries involved five left shoulders and three right shoulders. Six shoulders were injured in motor vehicle accidents, and two in falls from height.

Signs and symptoms related to the injury were numerous and included ipsilateral upper extremity cyanosis and swelling, weakness, and subjective numbness or tingling (five patients), dyspnea (two patients), and dysphagia (one patient). All patients had marked pain in the region of the sternoclavicular joint. In three patients, the pain was exacerbated by lying supine or in the lateral decubitus position. Injuries were isolated to the sternoclavicular joint in six patients. The remaining two patients sustained a number of associated injuries, including facial fracture, vertebral and extremity fractures, and pulmonary as well as cardiac contusion.

FIGURE 3

Treatment consisted of closed reduction employing an abduction traction technique. (4, 33, 34) The reduction was performed on the day of injury in six patients, one day after injury in one patient; and ten days after injury in one patient The abduction traction method of reduction is performed by placing the patient in the supine position with the dislocated shoulder near the edge of the table with a sandbag three to four inches thick between the shoulders. Lateral traction is applied to the abducted arm, which is then gradually brought back into extension. It is important to emphasize that traction always preceded extension of the arm to prevent the anterior aspect of the medial clavicle from binding on the posterior surface of the manubrium. (Figure 3) When this technique was unsuccessful, the skin over the medial clavicle was prepared and draped in surgical fashion and a sterile towel clip was used to facilitate the reduction by encircling the medial clavicle and applying lateral and anterior traction. Reduction of the posterior sternoclavicular joint injury was confirmed by computerized tomography.

GROUP II (OPERATIVE TREATMENT)

Group II consisted of thirteen patients, eleven male and two female, who had an average age of thirty-six years (range, twenty-four to forty-five years). Ten right shoulders and three left shoulders were injured. Eight shoulders were injured in motor vehicle accidents, two shoulders in sporting events (rodeo), two shoulders in a fall, and one when a horse crushed the patient.

All patients had pain in the region of the sternoclavicular joint. In three patients, the pain was exacerbated by lying supine or in the lateral decubitus position. Signs and symptoms included shortness of breath or dyspnea on exertion (seven patients), dysphagia or a choking sensation (four patients), ipsilateral upper extremity cyanosis and swelling, weakness, and subjective numbness or tingling (four patients), and a dysphoric sensation associated with tachycardia and diaphoresis while performing manual labor (one patient). Associated injuries included multiple rib fractures and pneumothorax (four patients), pulmonary contusion (three patients), and cardiac contusion, facial fractures, subclavian artery psuedoaneurism, and subclavian vein stenosis (one patient). The indications for operation were failed closed reduction, recurrent posterior sternoclavicular dislocation, and remaining or progressive symptoms attributed to the posteriorly displaced medial clavicle. Nine patients demonstrated a fixed posterior displacement of the medial clavicle because of scarring and soft tissue contracture that we related to the chronicity of the displacement. Three patients had recurrent posterior sternoclavicular dislocation with forward elevation of the ipsilateral upper extremity. The posterior displacement of the medial clavicle was associated with dyspnea and would spontaneously reduce when the arm was adducted to the patient's side while the shoulders were simultaneously retracted. The final patient demonstrated postreduction instability, which could not be maintained with bracing.

Operations were performed at an average of five months following injury (range, one day to eighteen months). At the time of operation, the mediastinal space was decompressed by medial clavicle excision. An integral component of the procedure was stabilization of the clavicle to the first rib by repair or reconstruction of the costoclavicular joint.

OPERATIVE TECHNIQUE

The patient is positioned supine on the operating table with three or four towels or a sandbag between the scapulae. The skin incision parallels the superior border of the medial clavicle and extends over to the notch of the manubrium and down over the anterior surface of the manubrium. The periosteum of the clavicle is incised in line with the skin incision and preserved for later closure. The clavicular head of the sternocleidomastoid muscle and the clavicular origin of the pectoralis major muscle are reflected subperiosteally to facilitate exposure of the sternoclavicular joint. In a true sternoclavicular dislocation with disruption of the costoclavicular ligament the medial 1.5 to 2.0 cm of the clavicle is resected, with care taken not to damage the vascular structures that are posterior to the medial clavicle and sternoclavicular joint. This resection is performed by placing a curved Crego retractor or a small ribbon retractor behind the clavicle at the intended osteotomy site. (Figure 4a, 4b) After the medial clavicle has been resected, three or four pieces of 1-mm Cottony Dacron sutures (Deknatel, Fall River, Massachusetts) are passed round the remaining medial end of the clavicle and its periosteal tube and then through the residual costoclavicular ligament and periosteum on the dorsal surface on the first rib to stabilize the medial clavicle. In the shoulders in this series, the costoclavicular ligaments were found to be intact on the periosteal sleeve and repair of the periosteum reapproximated the ligaments to the medial clavicle. After closing the periosteum, the sternoclavicular joint can be farther stabilized with several nonabsorbable (Figure 5) sutures, which are passed around the medial clavicle and secured to the remaining intact costoclavicular ligament (36).

FIGURE 4a

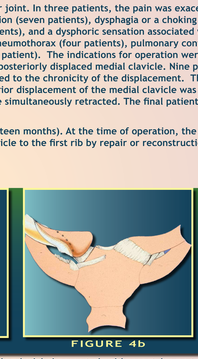

FIGURE 4b

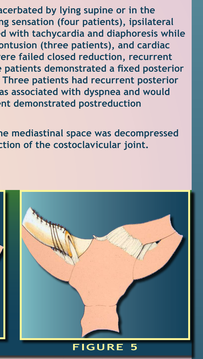

FIGURE 5

POSTCARE MANAGEMENT

Postoperatively, the shoulders were held in a position of scapular retraction for six to eight weeks with a figure-of-eight dressing or a commercially available clavicle strap. The patients were allowed to perform gentle pendulum exercises but were cautioned against active flexion or abduction of the shoulder above 90 degrees. Forceful pushing, pulling, and lifting were avoided for three months. Beginning at twelve weeks, the patient was instructed in a physician-directed rehabilitation program of stretching and strengthening exercises.

Bibliography

1. Borowiecki B, Charow A, Cook W, Rozycki D, and Thaler S: An unusual football injury (posterior dislocation of the sternoclavicular joint). Arch Otolaryngol 95:185-187, 1972.
2. Borrero E: Traumatic posterior displacement of the left clavicular head causing chronic extrinsic compression of the subclavian artery. Physician Sports Med 15:87-89, 1987.
3. Brown JE: Anterior sternoclavicular dislocation: a method of repair. Am J Orthop 31:184-189, 1961.
4. Buckerfield CT and Castle ME: Acute traumatic retrosternal dislocation of the clavicle. J Bone Joint Surg Am 66(3):379-384, 1984.
5. Carmichael, KD, Longo, A: Posterior sternoclavicular epiphyseal fracture dislocation with delayed diagnosis. Skeletal Radiology 35 (8):608-612, 2006
6. Clark RL, Milgram JW, and Yawn DH: Fatal aortic perforation and cardiac tampon due to a Kirschner wire migrating from the right sternoclavicular joint. South Med J 67:316-318, 1974.
7. Denham RH Jr and Dingley AF Jr: Epiphyseal separation of the medial end of the clavicle. J Bone Joint Surg Am 49:1179-1183, 1967.
8. Eskola A: Sternoclavicular dislocation: a plea for open treatment. Acta Orthop Scand 57:227-228, 1986.
9. Ferrandez L, Yubero J, Usabiaga J, Nu L, and Martin F: Sternoclavicular dislocation, treatment and complications. Ital J Orthop Traumatol 14:349-355, 1988.
10. Fery A and Sommelet I: [Sternoclavicular dislocations. Observations on the treatment and result of 49 cases] [French]. Int Orthop 12(3):187-95, 1988.
11. Frank WW, Jannash O, Slassi M, Henning FF: Balser plate stabilization: an alternative therapy for treating sternoclavicular instability. J Shoulder Elbow Surg: 12 (3): 276-281, 2003.
12. Gale DW, Dunn ID, McPherson S, and Oth OOk Retrosternal dislocation of the clavicle: the "stealth" dislocation: a case report. Injury 23:563-564, 1992.
13. Gangahar DM and Flogaites T: Retrosternal dislocation of the clavicle producing thoracic outlet syndrome. J Trauma 18:369-372, 1978.
14. Gardner MA and Bidstrup BP: Intrathoracic great vessel injury resulting from blunt chest trauma associated with posterior dislocation of the sternoclavicular joint. Aust NZ J Surg 53:427-430, 1983.
15. Gerlach D, Wemhoner SR, and Ogbuihi S: [On two cases of fatal heart tamponade due to migration of fracture nails from the sternoclavicular joint] [German]. Z Rechtsmed 93:53-60, 1984.
16. Gobert R, Meuli M, Altematt S: Medial clavicular ephysiolysis in children; the so called sternoclavicular dislocation. Emerg Radiol 10:252-255, 2004.
17. Greenlee DP: Posterior dislocation of the sternal end of the clavicle. JAMA 125:426-428, 1944.
18. Howard FM and Shafer SJ: Injuries to the clavicle with neurovascular complications: a study of fourteen cases. J Bone Joint Surg Am 47:1335-1346, 1965.
19. Jain S, Monballiu D, Thompson JF: Thoracic outlet syndrome caused by chronic retrosternal dislocation of the clavicle. J Bone Joint Surg Br 84:116-118, 2002.
20. Kennedy JC: Retrosternal dislocation of the clavicle. J Bone Joint Surg Br 31:74-75, 1949.
21. Leonard JW and Gifford RW: Migration of a Kirschner wire from the clavicle into pulmonary artery. Am J Cardiol 16:598-600, 1965.
22. Lyons FA and Rockwood CA Jr: Migration of pins used in operations on the shoulder. J Bone Joint Surg Am 72(8): 1262-7, 1990.
23. McKenzie 1MM: Retrosternal dislocation of the clavicle: a report of two cases. J. Bone Joint Surg Br 45:138-141, 1963.
24. Mitchell WI and Cobey MC: Retrosternal dislocation of the clavicle. Med Ann DC 29:546-549, 1960.
25. Mirza AH, Alam K, Ali A. Posterior sternoclavicular dislocation in a rugby player as a cause of silent vascular compromise. Br J Sports Med. 39:28, 2005.
26. Nakayama E, Tanaka T, Noguchi T. Tracheal stenosis caused by retrosternal dislocation of the right clavicle. Ann Thorac Surg 83:685-687, 2007.
27. Nettles JL and Linscheid R Sternoclavicular dislocations. JTraumaB:158-164, 1968.
28. Pate 1W and Wilhite J: Migration of a foreign body from the sternoclavicular joint to the heart: a case report. Am Surg 35:448-449, 1969.
29. Patterson DC: Retrosternal dislocation of the clavicle. J Bone Joint Sing Br 43:90-92, 1961.
30. Pfister U and Weller S: [Luxation of the sternoclavicular joint (author's transl)] [German]. Unfallchir 8:81-87, 1982.
31. Poland I: Traumatic separation of epiphyses of the upper extremity. London Smith, Elder, & Co., 1898, pp 135-143.
32. Rayan GM: Compression brachial plexopathy caused by chronic posterior dislocation of the sternoclavicular joint. J Obb State Med Assoc 87:7-9, 1994.
33. Rockwood CA Jr and Wirth MA: Disorders of the sternoclavicular joint. In Rockwood CA Jr, Matsen FA 111 Harryman DT arid Wirth MA (eds): The Shoulder, 2nd Ed Philadelphia WB Saunders, 1998, pp 555-610.
34. Rockwood CA Jr; Dislocation of the sternoclavicular joint. In Rockwood CA Jr and Green DP (eds.): Fractures, 1st Ed, and vol. 1. Philadelphia: JB Lippincott, 1975, pp 756-787.
35. Rockwood CA Jr injuries of the sternoclavicular joint [abstract]. Orthop Trans 6:422, 1982.
36. Rockwood CA Jr; Groh, GI; Wirth, MA, Grassi, FA: Resection Arthroplasty of the Sternoclavicular Joint. J Bone Joint Surg Am 79(3):387-393, Mar 1997
37. Salvatore JE: Sternoclavicular joint dislocation. Clin Orthop (58):51-54, 1968.
38. Selesnick FH Jabion M-, Frank C, and Post M: Retrosternal dislocation of the clavicle. Report of four cases. J Bone Joint Surg Am 66(3):287-291, 1984.
39. Simurda MA: Retrosternal dislocation of the clavicle: a report of four cases and a method of repair. Canadian J Surg 11(4):487-90, 1968.
40. Smolle-Juettner FM, Holle PH Pistor H, Friehs G, and Szyskowitz R: Iatrogenic malpositioning of a sternoclavicular fixation wire. J Orthop Trauma 6:102-105, 1992.
41. Wasylenko MJ and Busse EF: Posterior dislocation of the clavicle causing fatal tracheoesophageal fistula. Can J Surg 24:626-627, 1981.
42. Wirth MA and Rockwood CA: Chronic conditions of the acromioclavicular and sternoclavicular joints. In Chapman M (ed): Operative Orthopaedics, Part XI- 2nd 4 Philadelphia: JB Lippincott, 1992, pp 37-44.
43. Wirth MA and Rockwood CA: Complications following repair of the sternoclavicular joint, in Bigliani L (ed): Complications of the Shoulder. Baltimore: Williams and Wilkins, 1993,.pp 139-153.
44. Wirth MA and Rockwood CA: Complications of treatment of injuries to the shoulder. In Epps C (ed): Complications in Orthopaedic Surgery, 3rd 4 Philadelphia: JB Lippincott, 1994, pp.229-255.
45. Wirth MA and Rockwood CA: Acute and chronic traumatic injuries of the sternoclavicular joint. JAAOS 1996; 4(5):268-278
46. Worman LW and Leagus C: Intrathoracic injury following retrosternal dislocation of the clavicle. J Trauma 7:416-423, 1967.
47. Zucman J, Rebind L, and Aubart I: [Treatment of sternal dislocations of the clavicle (author's transl)] [French]. Rev Chir Orthop 64(1):35-43, 1978.

RESULTS

The average length of follow-up was five years (range, two to sixteen years). Results were evaluated with respect to pain, function, range of motion, strength, and patient satisfaction according to a modification of the University of California at Los Angeles Rating Scale (Table 1). Overall, eighteen of twenty-one patients were graded as good or excellent with considerable improvement in the ratings for pain strength, motion, and the ability to carry out daily work and sports activities.

GROUP I

The shoulder scores for this group of patients ranged from twenty-four to twenty-eight points (mean, twenty-six points). Of the eight shoulders, three had an excellent result (Figure 5, 6) and four had a good result. Occasional, mild pain was noted in four patients. In one patient, this was associated with a subtle click or catching sensation localized to the sternoclavicular joint. Another patient described mild discomfort in the sternoclavicular joint during abrupt deceleration in a motor vehicle. This was an isolated incident and the transient discomfort was attributed to pressure from the shoulder strap of the safety restraints. One patient noted pain with golf and this was controlled with intermittent use of nonsteroidal antiinflammatory medication.

All eight patients were able to use the involved limb above shoulder level for activities of daily living, work and sports. Four patients reported normal function with all activities while four patients noted a slight restriction. All patients demonstrated more than 150 degrees of active elevation and were satisfied with the results of treatment.

GROUP II

An excellent result was achieved in five of the thirteen operatively treated shoulders, a good result in six, and a fair result in two. The shoulder scores for this group of patients ranged from twenty-two to thirty points (mean, twenty-seven points). Occasional or no pain was present in eleven shoulders. Mild pain with overhead use of the arm or bench-press weight lifting was noted in two patients. All patients had more than 150 degrees of active elevation. Seven patients reported normal function with all activities of daily living, work, and sports. Six of these patients were involved in heavy manual labor which included working in feed lots, saddle riding, bucking hay, and breaking horses. The seventh was a real estate appraiser. Three patients had slight restriction while using the involved limb above shoulder level for various sport or work activities. Three patients had more than slight restriction when using the limb above shoulder level but were unrestricted when the limb was used below the level of the shoulder. Two patients reported no change in work. The remaining patient was a heavy equipment operator and carpenter who changed his vocation to minimize overhead activity, which was associated with occasional discomfort.

FIGURE 6

FIGURE 7

DISCUSSION

The complications associated with an unreduced posterior sternoclavicular dislocation are numerous and include thoracic outlet syndrome with swelling and cyanosis of the upper extremity (4, 13, 30) vascular compromise (1, 13, 14, 18, 46) brachial plexus injury, (4, 27, 38) and fatal tracheoesophageal fistula. (41). Buckerfield and Castle reported successful closed reduction of a traumatic posterior sternoclavicular dislocation or posterior physeal fracture-dislocation in six of seven patients ranging in age from thirteen to twenty-six years. (4) In their patients, reduction was achieved by retraction of the shoulders with caudal traction on the adducted arm while an interscapular bolster supported the patients. Closed reduction was accomplished within twenty-four hours after injury in six patients and at ninety-six hours after injury in one patient. One patient demonstrated postreduction instability, but the reduction was maintained by holding the shoulders in full retraction with a figure-of-eight clavicular strap. Two of their patients were lost to follow-up, and the remaining five patients had full range of motion without pain discomfort, or deformity at a mean follow-up often months. Our experience with early closed reduction was similar to theirs in that seven patients were reduced within twenty-four hours of injury and one patient was reduced ten days after injury. The fact that one of the injuries in our series was reduced ten days after injury suggests that closed reduction may be successful even after ten days.

Several authors have recommended open reduction when closed reduction has failed, because of the potential problems that can be associated with posterior displacement of the medial clavicle into the mediastinum. (2, 33, 34, 39, 42-45) In our series, operative management consisted of decompression of the mediastinum by excision of the medial clavicle. The residual clavicle was then stabilized to the costoclavicular ligament and the periosteum of the first rib. In 1967, Denham and Dingley reported three cases of medial clavicle physeal injury in patients fourteen to sixteen years of age (7). They demonstrated at surgery that the pathology was indeed a physeal fracture of the medial clavicle. This is important information to remember because many so-called dislocations of the sternoclavicular joint are not dislocations but physeal injuries, as the medial clavicular epiphysis does not close until the twenty-third to twenty-fifth year. (5, 17, 34)

Various authors have recommended open reduction and internal fixation for acute injuries, as well as for chronic problems, (8-11,30,47) While we agree that unreduced acute or chronic posterior sternoclavicular dislocations should be managed operatively, we believe that the placement of pins across the sternoclavicular joint is contra-indicated because of the many serious complications that can occur with this technique. We are aware of seven deaths (6,15,21,27,37,40) and three near deaths (3,28,45) from complications of transfixing the sternoclavicular joint with Kirschner wires or Steinmann pins. The pins, either intact or broken, migrated into the heart, pulmonary artery, innominate artery, or aorta. In 1990, Lyons and Rockwood (22) reviewed the literature regarding the migration of pins and similar devices that were used in operations on the sternoclavicular joint. The number of patients who needed a thoracotomy, sternotomy, vascular repair, laminectomy, or laparotomy confirmed the seriousness of migration of pins from the sternoclavicular joint. They concluded that the risk of migration after fixation of the sternoclavicular joint with pins to be so great and grave as to absolutely contraindicate their use in surgical procedures on this joint.

In conclusion, patients in both groups compared favorably in terms of improvement in ratings for pain, strength, motion, and the ability to perform work and sports. Early recognition of the injury seems to improve the probability that closed reduction will be successful. Moreover, once the joint has been reduced closed, it is usually stable. In the present series, early recognition of injury followed by closed reduction and figure-of-eight immobilization was highly successful, obviated the risks of operation, and resulted in an outcome, which compared favorably with operative treatment. When treated late or closed reduction fails, open reduction combined with reconstruction of the costoclavicular ligaments, results in a stable construct.

TABLE I.

Modification of the Rating Scale of the University of California at Los Angeles

CATEGORY	Points
PAIN	
Constant and unbearable; frequent use of strong medication	1
Constant but bearable; occasional use of strong medication	2
Present during light activities; none or little during rest frequent use of salicylates	4
Present during strenuous or particular activities only; occasional use of salicylates	6
Occasional	8
None	10
FUNCTION	
Patient unable to use limb	1
Limb used for light activities only	2
Limb used for light housework and most activities of daily living	4
Limb used for most housework shopping, driving; combing hair; dressing and undressing, including fastening brassiere	6
Slight restriction only, limb used for work above shoulder level	8
Normal activities	10
ACTIVE FORWARD FLEXION	
<30°	0
30°to<45°	1
45°toc90°	2
90°to<120°	3
120°to<150°	4
>150°	5
STRENGTH AND PATIENT SATISFACTION	
Less and not satisfied	0
Better and satisfied	5
SCORE RATING SCALE	
Excellent, 27-30 points	
Good, 24-26 points	
Fair, 21-23 points	
Poor, 20 points or less	