

Capsulorrhaphy Through an Anterior Approach for the Treatment of Atraumatic Posterior Glenohumeral Instability with Multidirectional Laxity of the Shoulder*†

BY MICHAEL A. WIRTH, M.D.‡, GORDON I. GROH, M.D.§, AND CHARLES A. ROCKWOOD, JR., M.D.‡, SAN ANTONIO, TEXAS

Investigation performed at the Shoulder Service, University of Texas Health Science Center at San Antonio, San Antonio

ABSTRACT: Between June 1983 and March 1992, we performed a capsular reconstruction procedure through an anterior approach in ten patients (ten shoulders) who had multidirectional laxity of the shoulder and symptomatic atraumatic posterior glenohumeral instability. The procedure included closure of the capsule in the rotator interval and imbrication of the anterior, inferior, and posteroinferior aspects of the capsule by a double-breasting technique that decreases the overall capsular volume.

The mean duration of follow-up was sixty months (range, twenty-four to 103 months). According to the system of Rowe and Zarins, the result was graded as excellent for five shoulders, good for four, and poor for one. On the basis of our results, we recommend capsular reconstruction through an anterior approach only in patients who have persistent multidirectional laxity and symptomatic atraumatic posterior instability of the shoulder despite participation in an intensive rehabilitation program.

Multidirectional glenohumeral laxity with atraumatic posterior glenohumeral instability is best treated with a program of physical therapy that emphasizes strengthening of the deltoid, rotator-cuff, and scapular stabilizer muscles^{3,12,15,20,26,27}. Occasionally, involuntary subluxations or dislocations persist despite the patient's compliance with an extensive rehabilitation program. Operative intervention is considered only for patients who remain symptomatic or disabled. The most frequently performed operation is the posterior capsular shift procedure described by Neer and Foster²³. Other procedures include various types of soft-tissue reconstructions^{11,13,18,23,26,27,29}, osteotomy of the posterior part of the glenoid^{17,31}, posterior bone block^{5,6,22}, or derotation osteotomy of the proximal part of the humerus¹.

There is considerable controversy regarding the

most appropriate procedure for the treatment of such shoulders; the controversy may be due to the poor results reported after all types of posterior reconstructions^{2,11,14,16}. Successful treatment of recurrent traumatic or atraumatic instability of the shoulder with use of a posterior approach can be quite difficult; rates of failure between 8 percent (two of twenty-four shoulders)¹² and 45 percent (nine of twenty shoulders)³³ have been reported. One possible reason for these failures is the poor quality and insubstantial nature of the posterior part of the capsule, which preclude a strong reconstruction. Furthermore, unlike capsulolabral injuries, which are often seen with traumatic anterior instability of the shoulder and are amenable to operative repair, associated fractures involving the posterior aspect of the glenoid rim or the anteromedial part of the humeral head are less frequent^{7,12,33}. The pathological changes associated with atraumatic posterior instability are often limited to minor abnormalities such as fraying or partial separation of the labrum. Another reason for the poor results associated with the posterior operative approach may be the failure to recognize the presence of multidirectional laxity in association with the posterior instability of the shoulder.

We report on a small group of patients with multidirectional laxity as well as posterior instability of the shoulder who had a capsular reconstruction through an anterior approach.

Materials and Methods

Eleven consecutive patients (eleven shoulders) who had recurrent atraumatic posterior instability and multidirectional laxity of the shoulder as well as generalized ligamentous laxity were evaluated and managed by the senior one of us (C. A. R., Jr.) between 1983 and 1992. One patient was lost to follow-up. The mean age of the six female and four male patients was twenty-three years (range, sixteen to thirty-five years) (Table I). The dominant extremity was involved in seven patients and the nondominant extremity, in three.

Six patients initially had been referred with a diagnosis of traumatic posterior glenohumeral instability. However, after a careful history had been recorded and a physical examination and a review of the radiographs had been performed, all six patients were found to have

*No benefits in any form have been received or will be received from a commercial party related directly or indirectly to the subject of this article. No funds were received in support of this study.

†Read in part at the Annual Meeting of the American Shoulder and Elbow Surgeons, Atlanta, Georgia, February 25, 1996.

‡Department of Orthopaedics, University of Texas Health Science Center at San Antonio, 7703 Floyd Curl Drive, San Antonio, Texas 78284-7774.

§129 McDowell, Asheville, North Carolina 28801.

TABLE I
DATA ON THE PATIENTS

Case	Gender, Age (yrs.)	Occupation	Affected Side/ Dominant Side	Previous Procedures	Operative Findings	Duration of Follow-up (mos.)	Result	Initial Injury
1	F, 35	Gymnastics coach	L/R	Putti-Platt	Absence of anterior aspect of glenoid labrum, degenerative changes in pos- terior part of glenoid, capsular redundancy	61	Good	Traumatic dislocation sustained on amusement- park ride*
2	F, 25	Manufacturing supervisor	R/R	None	Partial detachment of posterior aspect of glenoid labrum, capsular redundancy	31	Excellent	Traumatic subluxation sustained in motorcycle accident*
3	F, 16	Student	R/R	None	Absence of anterior aspect of glenoid labrum, capsular redundancy	87	Good	Traumatic dislocation sustained while high-jumping*
4	M, 17	Student	R/R	None	Capsular redundancy	103	Excellent	Atraumatic subluxation sustained while playing football
5	F, 20	Student	R/R	Posterior capsulorrhaphy	Complete absence of glenoid labrum, capsular redundancy	65	Excellent	Atraumatic subluxation sustained while swimming
6	F, 19	Physical therapist	R/R	None	Capsular redundancy	24	Poor	Atraumatic subluxation sustained while playing basketball
7	F, 30	Laboratory assistant	L/R	Boyd-Sisk, posterior cap- sulorrhaphy, arthroscopic débridement, biceps tenodesis, arthroscopic débridement	Anteromedial defect of hu- meral head with exostosis, degenerative changes in pos- terior part of glenoid, capsu- lar redundancy	24	Good	Traumatic dis- location sus- tained while playing basketball*
8	M, 27	Construction worker	R/R	None	Degenerative changes in inferior and posteroinferior parts of glenoid labrum, capsular redundancy	36	Excellent	Traumatic subluxation after fall*
9	M, 16	Student	L/R	Posterior capsulorrhaphy	Vertical cleft in posterior part of glenoid labrum, capsular redundancy, partial detach- ment of posterior part of glenoid labrum	92	Excellent	Traumatic subluxation after fall*
10	M, 27	Truck driver	R/R	None	Capsular redundancy	72	Good	Atraumatic subluxation after fall

*Although the injury appeared to have been caused by a traumatic episode, multidirectional glenohumeral laxity with atraumatic posterior instability was found.

multidirectional glenohumeral laxity with posterior instability of the shoulder. To establish the diagnosis, the pertinent questions should focus on the initial episode;

the nature, mechanism, and force of the traumatic event; the position of the arm at the time of the injury; and the degree of pain at the time of the initial injury and during

convalescence. Patients who have multidirectional laxity and posterior instability of the shoulder usually report a minor traumatic event such as throwing a ball. The displacement, in most instances, is spontaneously reduced; there is little discomfort after the reduction, and the patients usually return to their usual activities immediately or within a few hours after the incident. Forward elevation of the shoulder between 90 and 120 degrees may cause the shoulder to sublunate posteriorly. The patient may also report laxity of the contralateral shoulder, which sublunates during certain maneuvers.

Initially, all of the patients were managed with an exercise regimen designed to strengthen the three parts of the deltoid, the rotator-cuff muscles, and the scapular stabilizer muscles with use of progressive resistance³. They participated in the rehabilitation program at our institution for a mean duration of fourteen months (range, three to twenty-four months) and were seen at intervals of six to eight weeks during that time-period. If the examination at three months revealed no improvement in stability, a reconstruction procedure that included closure of the defect in the superior part of the rotator interval capsule and imbrication of the anterior, inferior, and posteroinferior parts of the capsule was recommended.

Nine patients identified a specific event that had caused the injury. The only association that the tenth patient could make with the injury was competitive swimming. In seven patients, the initial injury of the shoulder was a posterior glenohumeral sublunation or dislocation that reduced spontaneously. The remaining three patients had a frank dislocation that was reduced by a trainer or an emergency-room physician, but the patients had little discomfort after the reduction and were able to return to their usual activities within a few hours. All patients continued to have symptomatic posterior instability with activities of daily living, work, and sports. Two patients also had pain at rest. Three patients described a clunk, jerking, or wobbly sensation with simple elevation of the shoulder above the horizontal plane.

Four patients had a history of multiple operations, which included Putti-Platt reconstruction, a Boyd-Sisk procedure, posterior capsular reconstructions, arthroscopic débridement, and biceps tenodesis. These four patients continued to have symptomatic recurrent posterior instability and discomfort with activities of daily living.

All of the patients demonstrated the posterior apprehension sign^{26,27} — that is, the symptoms were reproduced when the affected arm was placed in 90 degrees of forward elevation, slight adduction, and 30 degrees of internal rotation. None of the patients had an anterior apprehension sign when the arm was stressed in abduction and external rotation. Similarly, inferior drawer testing did not produce any evidence of apprehension, but six patients reported discomfort.

The degree of glenohumeral laxity was estimated

TABLE II
GRADING SYSTEM OF ROWE AND ZARINS²⁹

Criterion	No. of Points*
Function	
No limitation in sports or work, able to throw baseball and football, can swim crawl stroke	50
No limitation in work; slight limitation in throwing baseball, serving forcefully in tennis, or swimming crawl; can throw football normally	35
Moderate limitation in overhead work, throwing baseball and football, swimming crawl, or serving in tennis	20
Marked limitation in throwing and in all sports, unable to work overhead	0
Pain	
None	10
Moderate	5
Severe	0
Stability	
Negative apprehension test, no sublunation	30
Negative apprehension test but discomfort with arm in abducted and externally rotated position	15
Positive apprehension test and sense of sublunation	0
Motion	
Full range of motion	10
As much as 25 per cent loss of motion in any plane	5
More than 25 per cent loss of motion in any plane	0

*A score of 90 to 100 points indicated an excellent result; 70 to 89 points, a good result; 40 to 69 points, a fair result; and 39 points or less, a poor result.

with the drawer test and was classified with a modification of the method described by Cooper and Brems⁴. Grade-0 instability indicated a trace of laxity; grade-I, that the humeral head could be displaced by as much as 50 percent of its diameter; grade-II, that the humeral head could be translated by more than 50 percent of its diameter from its articulation with the glenoid but was not dislocatable; and grade-III, that the glenohumeral joint could be dislocated.

Preoperatively, posterior laxity was grade III in two shoulders and grade II in eight. Inferior laxity was classified as grade II in all shoulders. Anterior laxity was classified as grade II in eight shoulders and grade I in two. All patients demonstrated more than 90 degrees of hyperextension of the metacarpophalangeal joints, hyperabduction of the thumb toward the volar side of the forearm, and 15 degrees of recurvatum of the knees and elbows, which were consistent with generalized ligamentous laxity.

Anteroposterior, axillary, lateral, modified axillary (the so-called West Point axillary lateral²⁸), and Stryker notch²⁷ radiographs were made. An anteromedial defect of the humeral head (a reverse Hill-Sachs lesion) was seen in one patient; calcification along the posteroinferior aspect of the glenoid, in one; and erosion, blunting, or microfracture of the posterior aspect of the glenoid

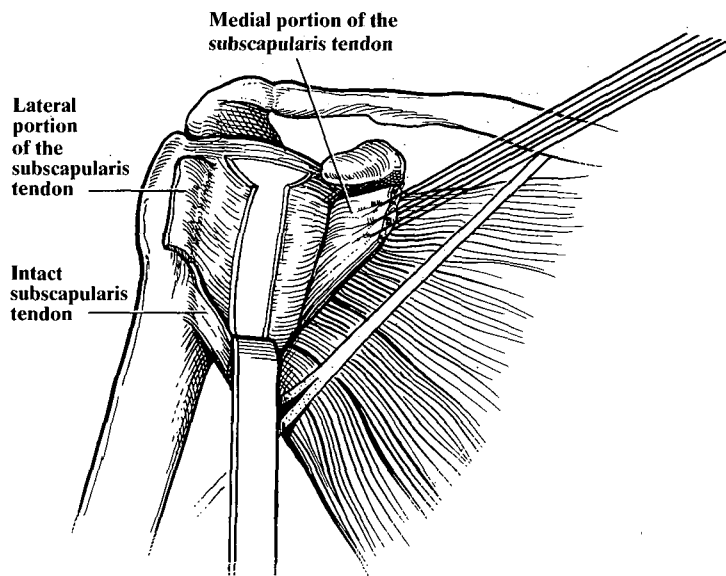


FIG. 1

Drawing showing the vertical division of the capsule, midway between its attachments on the glenoid rim and the humeral head.

rim, in two. The criteria described by Rowe and Zarins²⁹ were used to grade function, pain, stability, and motion (Table II).

Operative Procedure

All patients had the capsular imbrication procedure performed through an anterior axillary incision in the deltopectoral interval while in a beach-chair position. The capsulorrhaphy procedure described in the present report is a modification of the capsular imbrication procedure for the treatment of recurrent anterior glenohumeral instability that was previously described by the senior one of us^{20,26,35}. Several technical details of the procedure must be kept in mind. When the deltopectoral muscles are retracted, the clavipectoral fascia is seen covering the conjoined tendons and is divided vertically along the lateral border of the conjoined tendons. The axillary nerve is identified as it passes along the anteroinferior border of the subscapularis muscle and is protected with a Scofield retractor. With the arm in external rotation, the superior and inferior borders of the subscapularis tendon can be visualized and palpated. The superior two-thirds of the subscapularis tendon is carefully transected in a vertical direction, down to but not into the capsule. The incision is made two centimeters medial to its insertion onto the lesser tuberosity. When the vertical cut in the tendon has been completed, the medial part of the tendon is reflected off the capsule, with the use of curved Mayo scissors, until there are no additional connections between the tendon and the capsule. At this point, the defect in the rotator interval capsule is observed. This lesion is a superior capsular defect, which is seen in the interval between the supraspinatus and the subscapularis. These lesions vary in size but can involve most or all of the superior part of the capsule within the confines of the interval.

The capsule is then divided vertically, midway between its attachments on the glenoid rim and the humeral head (Fig. 1). The incision begins at the inferior border of the defect in the rotator interval capsule and extends inferiorly beyond the six o'clock position. The more laxity that is noted in the posterior aspect of the capsule, the more the capsular incision should be carried out posteriorly (Fig. 2). Exposure of the inferior and posteroinferior aspects of the capsule is facilitated by forward elevation, external rotation, and slight abduc-

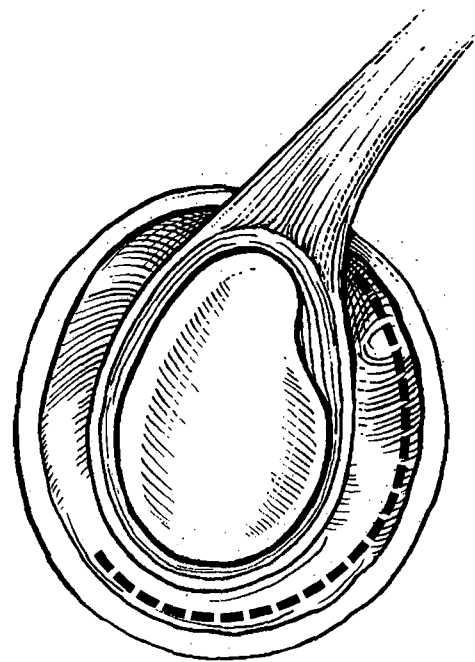


FIG. 2

Drawing showing the incision (broken line), which begins at the rotator interval capsule and extends to the posteroinferior aspect of the capsule.

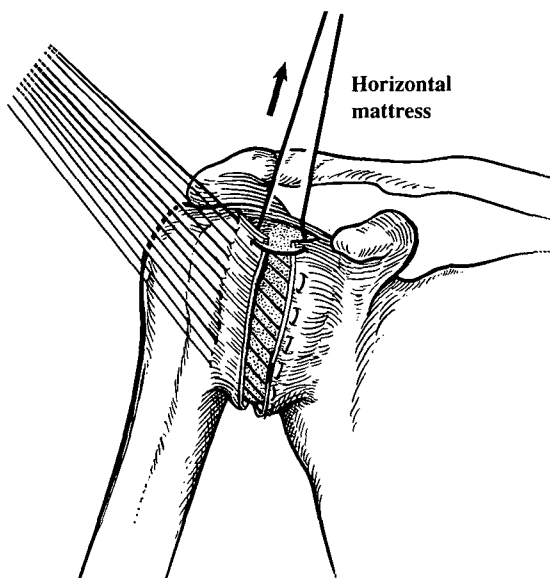


FIG. 3

Drawing showing the placement of the sutures for capsular imbrication.

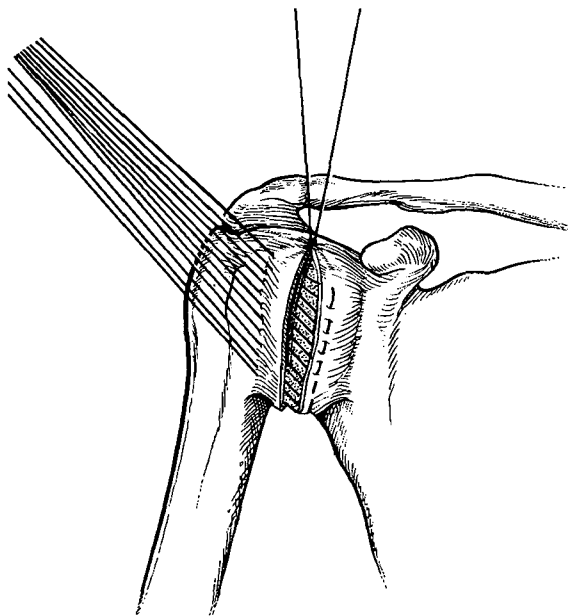


FIG. 4

Drawing showing closure of the defect in the rotator interval capsule and subsequent capsular imbrication.

tion of the arm in the scapular plane. Stay sutures are placed sequentially along the free edge of the medial capsular leaflet. The capsulotomy proceeds inferiorly and posteriorly, and the sutures allow traction on the medial capsular leaflet, which makes it possible to divide the most posteroinferior portion of the inferior glenohumeral ligament complex. This degree of capsular incision allows subsequent anterior advancement of the posterior portion of the inferior glenohumeral ligament complex.

After the capsulotomy is completed, the rotator cuff interval is closed with a horizontal mattress suture

with use of nonabsorbable number-2 Cottony Dacron (Deknatel, Fall River, Massachusetts) (Fig. 3). With the arm held in 25 degrees of external rotation, the medial aspect of the inferior glenohumeral ligament complex is shifted anteriorly and laterally and the remaining portion of the medial aspect of the capsule is shifted laterally and superiorly under the lateral capsular leaflet (Fig. 4). This step should eliminate any posterior capsular laxity. A finger placed in the axillary pouch between the anterior and posterior bands of the inferior glenohumeral ligament confirms elimination of the inferior and posteroinferior capsular laxity that existed previously. Next, the lateral aspect of the capsule is shifted superomedially and is sutured to the anterior surface of the medial aspect of the capsule (Fig. 5). In both phases of the capsular imbrication, the arm should be held in 25 degrees of external rotation, 20 degrees of abduction, and 0 degrees of forward elevation. If less than 30 degrees of passive external rotation is present at the conclusion of the procedure, there has been excessive tightening of the anterior structures and the procedure may push the humeral head out posteriorly¹⁹.

Postoperative Care

Postoperatively, a commercial shoulder immobilizer is worn for comfort, but the patient is encouraged to use the involved extremity for activities of daily living as early as the first postoperative day. During this time, the patient is instructed to exercise the hand, wrist, and elbow but is cautioned to avoid adduction, forward elevation, and internal rotation maneuvers that cause discomfort in the shoulder. For two weeks postoperatively, the immobilizer is worn whenever the patient goes outside his or her home. At two weeks, the sutures are removed. The stretching phase of the rehabilitation program is begun six weeks after the operation. When the patient has regained active elevation to within 20 to 30

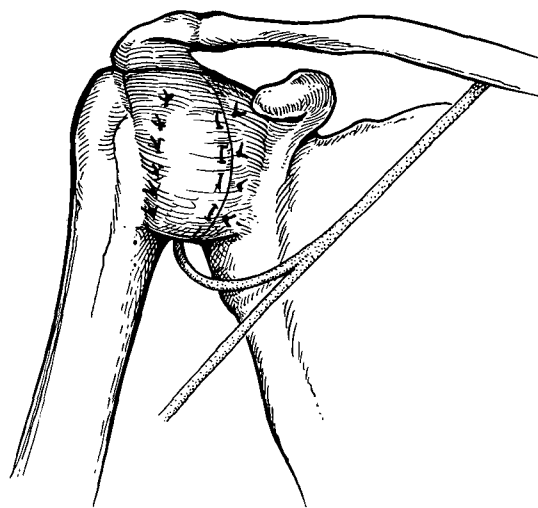


FIG. 5

Drawing demonstrating double-breasting of the lateral aspect of the capsule.

degrees of that on the normal side and rotation is about 50 to 60 percent of that on the normal side, the muscle-strengthening phase of the exercise program is initiated. This strengthening program is performed three or four times daily and emphasizes conditioning of the deltoid, rotator-cuff, and scapular stabilizer muscles³.

Results

The ten patients were followed for a mean duration of sixty months (range, twenty-four to 103 months). At the most recent physical examination, the patients responded to a questionnaire and were assessed according to the grading system of Rowe and Zarins²⁹. The result was graded as excellent for five shoulders, good for four, and poor for one.

Subjective Findings

The nine patients who had a good or excellent result reported a substantial improvement in function, and they had no recurrent instability. Six of the nine patients returned to the level of work and sports activities that they had performed before the onset of the symptomatic instability. The activities included track and football at the high-school level (two patients), collegiate basketball (one), and recreational sports (three). One patient who had played baseball before the initial injury was able to resume this sport but had to change from an outfield to an infield position. Another patient discontinued playing softball but continued to play golf. The one remaining patient discontinued participation in gymnastics because of an unrelated injury of the cervical spine. Pain was an infrequent postoperative symptom: only two patients had an occasional mild ache associated with changes in the weather. The follow-up radiographs of these two patients revealed unremarkable findings.

The one patient who had a poor result noted persistent symptoms and functional limitations associated with recurrent posterior instability. A follow-up examination eight weeks after the reconstruction of the shoulder demonstrated volitional posterior dislocation, and subsequent psychiatric evaluations revealed a latent emotional disorder.

Objective Findings

Intraoperatively, a capacious capsule with anterior, inferior, and posterior redundancy was seen in all ten patients. In particular, the inferior glenohumeral ligament complex was lax and had a large axillary pouch. As a result of multiple posterior subluxations over many years, three patients had erosive changes of the posterior aspect of the glenoid, two had a full-thickness defect of the cartilage that was confined to the posterior one-quarter of the articular surface of the glenoid labrum, and one had a vertical cleft in the posterior part of the labrum. One patient had an anteromedial defect of the humeral head, which occupied approximately 20 per-

cent of the diameter of the humeral head, and another had an exostosis of the anteromedial aspect of the humeral head. The anterior part of the glenoid labrum was absent in two shoulders, and the glenoid labrum was completely absent in one. The superior glenohumeral ligament was difficult to define in every shoulder because of the capsular defect. Similarly, the coracohumeral ligament was difficult to identify after it passed laterally from the base and the lateral border of the coracoid process, but it was presumed to represent the most superior border of the defect of the rotator interval capsule. No tears were found in the superior part of the labrum or the long head of the biceps tendon.

All but one shoulder was stable at the time of the most recent examination. Posterior glenohumeral laxity was grade I in eight shoulders, grade II in one, and grade III in one. Inferior glenohumeral laxity was grade I in nine shoulders and grade II in one. Anterior laxity was grade I in eight shoulders and grade II in two.

There were no operative complications.

The mean preoperative range of motion of the involved shoulder was 70 degrees (range, 20 to 90 degrees) of external rotation, 160 degrees (range, 130 to 180 degrees) of forward elevation, and internal rotation to the spinous process of the sixth thoracic vertebra (range, the twelfth to the fourth thoracic vertebra). The mean postoperative range of motion was 60 degrees (range, 15 to 65 degrees) of external rotation, 165 degrees (range, 130 to 180 degrees) of forward elevation, and internal rotation to the spinous process of the tenth thoracic vertebra (range, the third lumbar to the fifth thoracic vertebra).

At the time of follow-up, the mean range of motion of the contralateral shoulder was 65 degrees (range, 45 to 75 degrees) of external rotation and 170 degrees (range, 160 to 180 degrees) of forward elevation. Two patients had lost 5 and 50 degrees (mean, 28 degrees) of external rotation of the involved shoulder, and the remaining eight patients had no change in external rotation, compared with that of the normal shoulder.

Discussion

Patients who have multidirectional glenohumeral laxity and symptomatic recurrent posterior instability of the shoulder usually respond to a rehabilitation program that is designed to develop strong and coordinated function of the deltoid, rotator-cuff, and scapular stabilizer muscles³. When these measures fail, operative intervention is warranted in symptomatic patients.

The results of posterior reconstruction of the shoulder for the treatment of atraumatic recurrent posterior instability have not paralleled the success of anterior reconstruction for the treatment of atraumatic recurrent anterior glenohumeral instability. The most common reasons for failure of posterior procedures on the shoulder are high rates of recurrent instability and complications^{2,11,14,16,21,32}. Many of the complications noted in

the literature were the result of overzealous tightening of the posterior part of the capsule or of a posterior opening-wedge osteotomy, which can lead to paradoxical or anterior instability of the shoulder^{5,8,9,33}.

In 1984, Hawkins et al.¹² performed a retrospective study of fifty shoulders (in thirty-five patients) that had recurrent posterior instability. Most of the patients had an atraumatic dislocation of the shoulder that reduced spontaneously, and most demonstrated the instability during forward elevation with the arm internally rotated. However, unlike the patients in our series, those patients failed to demonstrate posterior apprehension on provocative stress-testing. The results of reconstruction were generally poor, with a recurrence of the instability in 50 percent (thirteen) of twenty-six shoulders and complications in five shoulders. In 1981, Tibone et al.³² reported the results of posterior staple capsulorrhaphy in ten patients who had recurrent posterior dislocation of the shoulder. A posterior Bankart lesion was found in all of the patients. There were several major complications, which included symptoms related to the hardware, postoperative adhesions, and symptomatic ectopic bone formation. In addition, three patients had recurrent posterior instability. In 1990, Tibone and Ting³³ reported the results of posterior staple capsulorrhaphy in twenty athletes who had recurrent posterior subluxation of the shoulder, eight of whom also had associated anterior instability. Six of the patients had recurrence of the posterior instability, and five of them had ligamentous laxity. Tibone and Ting concluded that posterior capsulorrhaphy alone was usually insufficient to restore stability to a shoulder that had atraumatic multidirectional instability.

Nobuhara and Ikeda²⁴ described a lesion of the rotator interval in 106 painful, unstable shoulders in 101 patients. However, they did not provide information about the onset of symptoms, the preoperative rehabilitation, or the presence of generalized ligamentous laxity, and they did not give relevant demographic data. The patients were characterized as having symptomatic posteroinferior glenohumeral subluxation during forward elevation of the involved upper extremity. However, on physical examination, most of the pain occurred during abduction and external rotation of the shoulder, suggesting a component of multidirectional instability. In contrast, preoperatively none of our patients had pain or apprehension when the arm was stressed in abduction and external rotation despite the fact that eight of the ten shoulders had grade-II anterior laxity (that is, the humeral head could be anteriorly translated more than 50 percent of its diameter from its articulation with the glenoid).

Warren et al.³⁴ studied posterior instability in twelve cadaveric specimens. After dividing the posterior structures of the shoulder, they grossly examined the effects on posterior translation of the glenohumeral joint. When the posterior muscles were excised, there was

no tendency for posterior dislocation to occur. When the posterior aspect of the capsule was subsequently incised, translation increased but the glenohumeral joint did not dislocate. For dislocation to occur when the arm was elevated, adducted, and internally rotated, the anterosuperior aspect of the capsule, in addition to the posterior aspect of the capsule, had to be incised between the twelve and three o'clock positions.

In another study of cadavera, Ovesen and Nielsen²⁵ demonstrated that the anterosuperior aspect of the shoulder capsule and the subscapularis tendon limited posterior glenohumeral translation even after sectioning of the entire posterior part of the capsule. Similarly, Schwartz et al.³⁰, who performed arthroscopically assisted selective sectioning of the shoulder capsule to quantitate the relative contribution of specific structures to glenohumeral stability, found that posterior glenohumeral dislocation did not occur after incision of the posterior part of the capsule unless the anterosuperior capsular structures also were sectioned. The superior glenohumeral ligament was found to provide secondary restraint to posterior instability of the shoulder. More recently, Harryman et al.¹⁰ investigated the role of the rotator interval capsule in passive motion and stability of the shoulder. The range of glenohumeral motion in cadaveric specimens was measured in the normal state, after selective capsular sectioning, and after imbrication of the rotator interval capsule. Operative modifications were found to alter several different parameters of shoulder motion, including rotation and translation, which ultimately affected the stability of the shoulder joint. Specifically, the intact rotator interval was found to be a major component of stability against posterior and inferior glenohumeral displacement. Posterior and inferior glenohumeral dislocations usually occurred after sectioning of the rotator interval capsule, whereas imbrication of this structure increased the resistance to translation in these directions. Harryman et al. concluded that patients who have inferior or posterior instability of the shoulder may benefit from an anterior reconstruction of the interval capsule.

On the basis of the findings in these earlier studies and the high rate of recurrent atraumatic posterior instability in patients who were managed with a posterior capsular shift procedure, the senior one of us began to reconstruct such shoulders through an anterior approach. The two essential components of the reconstruction involve closure of the rotator interval capsule and reduction of the excessive joint volume through a symmetrical and anatomical plication of the redundant anterior, inferior, and posteroinferior aspects of the capsule. The anterior approach offers the added advantage of stabilizing the shoulder through one incision as closure of the defect in the rotator interval capsule cannot be performed when a posterior approach is used for the stabilization procedure. There is only one indication for this operation: symptomatic atraumatic posterior in-

stability in patients who have multidirectional laxity of the shoulder and generalized ligamentous laxity despite participation in an intensive and extensive rehabilitation program. We wish to emphasize that we have performed this procedure in only thirteen patients during the last fourteen years. The paucity of such patients reflects the finding in a previous report by the senior one of us that 80 percent of patients who have atraumatic posterior instability of the shoulder respond favorably to an exercise program³. Because many patients who have posterior instability have a component of generalized ligamentous laxity, it appears that muscle-strengthening exercises can accommodate for capsular laxity of the shoulder. In contrast, exercises cannot consistently restore stability of the glenohumeral joint when fixed osseous architectural changes have occurred.

In summary, there is currently no consensus regarding the best treatment of recurrent symptomatic posterior glenohumeral instability. However, it is imperative to recognize the presence of underlying multidirectional laxity in association with atraumatic posterior glenohumeral instability of the shoulder before the selection of an operative procedure because a posterior capsular shift may not produce a successful result. We acknowledge that the anterior approach for operative treatment is unorthodox and represents a departure from the classic posterior operative options for the treatment of this problem. However, we are satisfied with our results in carefully selected patients, and we are encouraged by reports in the literature^{10,25,30,34} that support this method from a physiological and anatomical standpoint.

References

1. **Bateman, J. E.:** Fractures and dislocations. In *The Shoulder and Neck*, pp. 389-412. Edited by J. E. Bateman. Philadelphia, W. B. Saunders, 1972.
2. **Bayley, I. J. L., and Kessel, L.:** Posterior dislocation of the shoulder: the clinical spectrum. In Proceedings of the British Orthopaedic Association. *J. Bone and Joint Surg.*, 60-B(3): 440, 1978.
3. **Burkhead, W. Z., Jr., and Rockwood, C. A., Jr.:** Treatment of instability of the shoulder with an exercise program. *J. Bone and Joint Surg.*, 74-A: 890-896, July 1992.
4. **Cooper, R. A., and Brems, J. J.:** The inferior capsular-shift procedure for multidirectional instability of the shoulder. *J. Bone and Joint Surg.*, 74-A: 1516-1521, Dec. 1992.
5. **Dick, W., and Baumgartner, R.:** Hypermobilitat und wilkurliche hintere schulterluxatio. *Orthop. Praxis*, 16: 328-330, 1980.
6. **English, E., and Macnab, I.:** Recurrent posterior dislocation of the shoulder. *Canadian J. Surg.*, 17: 147-151, 1974.
7. **Fronek, J.; Warren, R. F.; and Bowen, M.:** Posterior subluxation of the glenohumeral joint. *J. Bone and Joint Surg.*, 71-A: 205-216, Feb. 1989.
8. **Gerber, C.; Ganz, R.; and Vinh, T. S.:** Glenoplasty for recurrent posterior shoulder instability. An anatomical reappraisal. *Clin. Orthop.*, 216: 70-79, 1987.
9. **Goss, T. P., and Costello, G.:** Recurrent symptomatic posterior glenohumeral subluxation. *Orthop. Rev.*, 17: 1024-1028, 1032, 1988.
10. **Harryman, D. T., II; Sidles, J. A.; Harris, S. L.; and Matsen, F. A., III:** The role of the rotator interval capsule in passive motion and stability of the shoulder. *J. Bone and Joint Surg.*, 74-A: 53-66, Jan. 1992.
11. **Hawkins, R. H., and Hawkins, R. J.:** Failed anterior reconstruction for shoulder instability. *J. Bone and Joint Surg.*, 67-B(5): 709-714, 1985.
12. **Hawkins, R. J.; Koppert, G.; and Johnston, G.:** Recurrent posterior instability (subluxation) of the shoulder. *J. Bone and Joint Surg.*, 66-A: 169-174, Feb. 1984.
13. **Hawkins, R. J., and McCormack, R. G.:** Posterior shoulder instability. *Orthopedics*, 11: 101-107, 1988.
14. **Hurley, J. A.; Anderson, T. E.; Dear, W.; Andrish, J. T.; Bergfeld, J. A.; and Weiker, G. G.:** Posterior shoulder instability: surgical vs. non-surgical results. *Orthop. Trans.*, 11: 458, 1987.
15. **Jobe, F. W.; Tibone, J. E.; Jobe, C. M.; and Kvitne, R. S.:** The shoulder in sports. In *The Shoulder*, edited by C. A. Rockwood, Jr., and F. A. Matsen, III. Vol. 2, pp. 983-986. Philadelphia, W. B. Saunders, 1990.
16. **Koppert, G., and Hawkins, R. J.:** Recurrent posterior dislocating shoulder. In Proceedings of the Canadian Orthopaedic Association. *J. Bone and Joint Surg.*, 62-B(1): 127-128, 1980.
17. **Kretzler, H. H., Jr., and Blue, A. R.:** Recurrent posterior dislocation of the shoulder in cerebral palsy. In Proceedings of the Western Orthopaedic Association. *J. Bone and Joint Surg.*, 48-A: 1221, Sept. 1966.
18. **Leyder, P.; Augereau, B.; and Apoil, A.:** Traitement des luxations postérieures invétérées de l'épaule par double abord et butée osseuse rétro-glénoïdienne. A propos de quatre observations. *Ann. chir.*, 34: 806-809, 1980.
19. **Lusardi, D. A.; Wirth, M. A.; Wurtz, D.; and Rockwood, C. A., Jr.:** Loss of external rotation following anterior capsulorrhaphy of the shoulder. *J. Bone and Joint Surg.*, 75-A: 1185-1192, Aug. 1993.
20. **Matsen, F. A., III; Thomas, S. C.; and Rockwood, C. A., Jr.:** Glenohumeral instability. In *The Shoulder*, edited by C. A. Rockwood, Jr., and F. A. Matsen, III. Vol. 1, pp. 526-622. Philadelphia, W. B. Saunders, 1990.
21. **Mowery, C. A.; Garfin, S. R.; Booth, R. E.; and Rothman, R. H.:** Recurrent posterior dislocation of the shoulder: treatment using a bone block. *J. Bone and Joint Surg.*, 67-A: 777-781, June 1985.
22. **Neer, C. S., II:** Degenerative lesions of the proximal humeral articular surface. *Clin. Orthop.*, 20: 116-124, 1961.
23. **Neer, C. S., II, and Foster, C. R.:** Inferior capsular shift for involuntary inferior and multidirectional instability of the shoulder. A preliminary report. *J. Bone and Joint Surg.*, 62-A: 897-908, Sept. 1980.
24. **Nobuhara, K., and Ikeda, H.:** Rotator interval lesion. *Clin. Orthop.*, 223: 44-50, 1987.
25. **Ovesen, J., and Nielsen, S.:** Posterior instability of the shoulder. A cadaver study. *Acta Orthop. Scandinavica*, 57: 436-439, 1986.
26. **Rockwood, C. A., Jr.; Thomas, S. C.; and Matsen, F. A., III:** Subluxations and dislocations about the glenohumeral joint. In *Rockwood and Green's Fractures in Adults*, edited by C. A. Rockwood, Jr., D. P. Green, and R. W. Bucholz. Ed. 3, vol. 1, pp. 1021-1180. Philadelphia, J. B. Lippincott, 1991.

27. **Rockwood, C. A., Jr., and Wirth, M. A.:** Subluxations and dislocations about the glenohumeral joint. In *Rockwood and Green's Fractures in Adults*, edited by C. A. Rockwood, Jr., D. P. Green, R. W. Bucholz, and J. D. Heckman. Ed. 4, vol. 2, pp. 1193-1339. Philadelphia, Lippincott-Raven, 1996.
28. **Rokous, J. R.; Feagin, J. A.; and Abbott, H. G.:** Modified axillary roentgenogram. A useful adjunct in the diagnosis of recurrent instability of the shoulder. *Clin. Orthop.*, 82: 84-86, 1972.
29. **Rowe, C. R., and Zarins, B.:** Recurrent transient subluxation of the shoulder. *J. Bone and Joint Surg.*, 63-A: 863-872, July 1981.
30. **Schwartz, R. E.; O'Brien, S. J.; Warren, R. F.; and Torzilli, P. A.:** Capsular restraints to anterior-posterior motion of the shoulder. *Orthop. Trans.*, 12: 727, 1988.
31. **Scott, D. J., Jr.:** Treatment of recurrent posterior dislocations of the shoulder by glenoplasty. Report of three cases. *J. Bone and Joint Surg.*, 49-A: 471-476, April 1967.
32. **Tibone, J. E.; Prietto, C.; Jobe, F. W.; Kerlan, R. W.; Carter, Y. S.; Shields, C. L., Jr.; Lombardo, S. J.; Collins, H. R.; and Vocum, L. A.:** Staple capsulorrhaphy for recurrent posterior shoulder dislocation. *Am. J. Sports Med.*, 9: 135-139, 1981.
33. **Tibone, J., and Ting, A.:** Capsulorrhaphy with a staple for recurrent posterior subluxation of the shoulder. *J. Bone and Joint Surg.*, 72-A: 999-1002, Aug. 1990.
34. **Warren, R. F.; Kornblatt, I. B.; and Marchand, R.:** Static factors affecting posterior shoulder stability. *Orthop. Trans.*, 8: 89, 1984.
35. **Wirth, M. A.; Blatter, G.; and Rockwood, C. A., Jr.:** The capsular imbrication procedure for recurrent anterior instability of the shoulder. *J. Bone and Joint Surg.*, 78-A: 246-259, Feb. 1996.