

# Pseudoaneurysm of the Axillary Artery with Median-Nerve Deficit after Axillary Block Anesthesia

## A CASE REPORT\*

BY GORDON I. GROH, M.D.†, BARRY J. GAINOR, M.D.†, JOEL T. JEFFRIES, M.D.†,  
MICHAEL BROWN, M.D.†, AND G. W. N. EGGERS, JR., M.D.†,  
COLUMBIA, MISSOURI

*From the Division of Orthopaedic Surgery, Department of Surgery,  
and the Department of Anesthesiology, University of Missouri Health Sciences Center, Columbia*

Regional anesthetic block of the major nerves in the axillary sheath at the level of the third part of the axillary artery is common. It is widely accepted because the artery and nerves are close to the skin, the technique is simple, and major complications are apparently absent<sup>3</sup>. This article presents a complication of axillary block anesthesia that, we believe, has not been reported before.

### Case Report

A sixty-five-year-old man had a twenty-six-year history of rheumatoid arthritis. An axillary block of the right brachial plexus was performed for an arthroplasty of a metacarpophalangeal joint on the right hand, with interposition of a spacer of silicone rubber. The patient's medical history included hypercholesterolemia, arteriosclerotic peripheral vascular disease, arteriosclerotic coronary artery disease, congestive heart failure, hypertension, peptic ulcer, and bronchospasm. He had been taking digoxin, furosemide, nifedipine, potassium chloride, cimetidine, naproxen, sulfasalazine, albuterol, and ipratropium bromide. An endarterectomy of the right carotid artery had been performed, and a resection arthroplasty of the metacarpophalangeal joints had been done on the left hand, with interposition of silicone-rubber spacers.

Laboratory studies done preoperatively showed that the prothrombin time, activated partial thromboplastin time, and platelet count were all normal. Bleeding time was not determined.

The anesthesiologist used a 25-gauge needle, 1.9 centimeters (0.75 inch), and an anesthetic mixture of 1 per cent lidocaine (thirty milliliters), 0.5 per cent lidocaine (fifteen milliliters), and sodium bicarbonate solution (five milliliters). The axillary sheath was located and was entered, and the anesthetic solution was injected at the sites associated with paresthesias in the distribution of the median and ulnar nerves. The artery was then located within the sheath by aspiration of blood, and the solution was injected posterior and anterior to the artery. The technique included constant aspiration with the exploratory needle, except when drugs were injected. The procedure was uneventful.

On the first postoperative day, the patient could wiggle the thumb and all of the fingers, and sensation in the right upper extremity was intact. Two days postoperatively, the patient complained of numbness in the hand. The symptoms were relieved when the dressing was loosened, and sensation was intact. The patient was discharged from the hospital on the following day.

He returned to the emergency room the next day because of pain.

\* No benefits in any form have been received or will be received from a commercial party related directly or indirectly to the subject of this article. No funds were received in support of this study.

† University of Missouri Health Sciences Center, 1 Hospital Drive, Columbia, Missouri 65212.

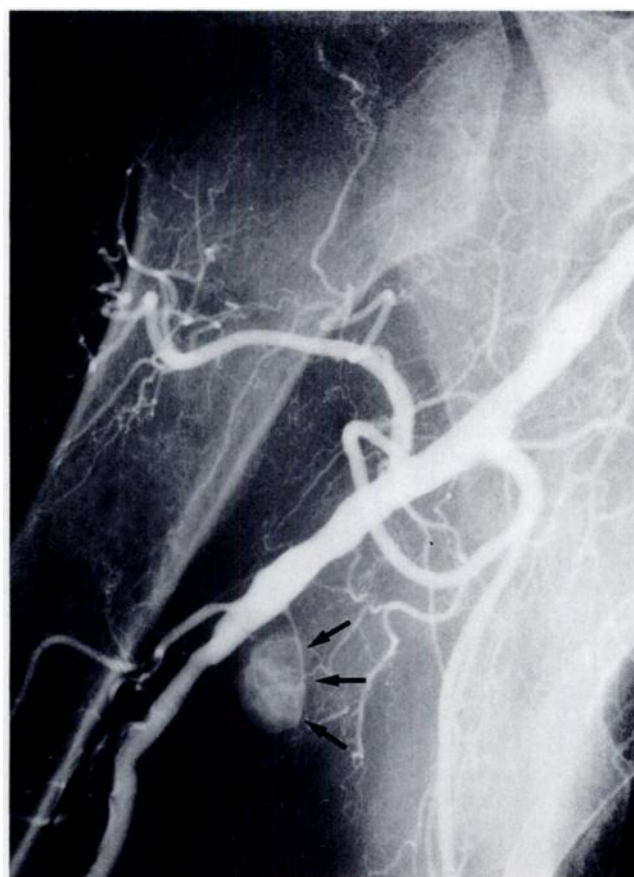


FIG. 1

Arteriogram of our patient, who had a severe deficit of the median nerve after axillary block anesthesia for an operation on the hand. Contrast medium (arrows) fills a well circumscribed pool, suggestive of a pseudoaneurysm.

There was mild erythema around the incision, and sensation in the thumb and in the index and long fingers was diminished. The patient was readmitted to the hospital to have antibiotic therapy for a possible mild cellulitis. The symptoms improved, and he was discharged from the hospital three days later.

Two weeks after the operation, the patient felt better, although some numbness persisted. He was referred to the occupational therapy department for active range-of-motion exercises. One month after the operation, the numbness was still present. The Tinel sign at the carpal tunnel and the Phalen maneuver were negative. A borderline carpal-tunnel syndrome was

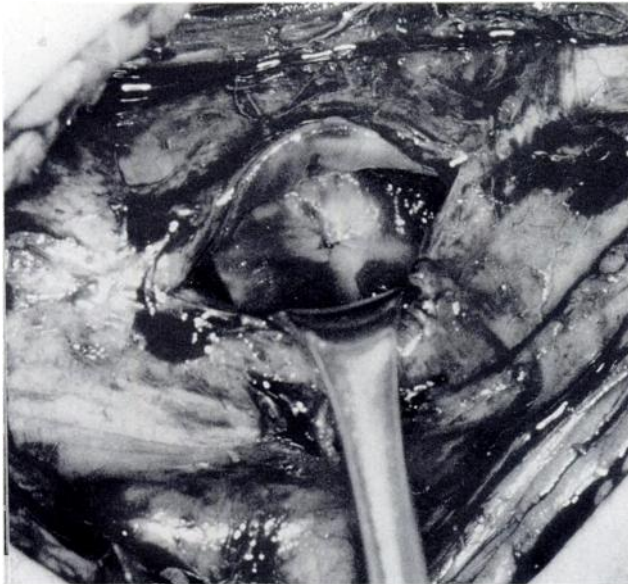

FIG. 2

An intraoperative photograph after excision of the pseudoaneurysm shows a single stitch closing the pin-hole-sized defect in the wall of the axillary artery.

suspected. Six weeks after the operation, it was found that the patient was unable to flex the distal joint of the index finger and thumb actively. Electrodiagnostic studies were scheduled.

Eight weeks after the operation, examination of the right axilla revealed a non-tender pulsatile mass, two by three centimeters in size. A bruit could be heard. Studies of nerve conduction revealed no response in all segments of the right median nerve distal to the pronator teres. The muscles that were supplied by the right median nerve had moderate numbers of fibrillations, positive sharp waves, and fasciculations. On arteriography, contrast medium from the axillary artery filled a well circumscribed pool, eleven by sixteen millimeters in size, three centimeters distal to the origin of the circumflex humeral branches of the artery (Fig. 1).

At the operation two weeks later, a pseudoaneurysm of the right axillary artery, three by three centimeters in size, was found overlying the medial cord of the brachial plexus. The apex of the mass was noted to impinge markedly on the median nerve where it was formed from the branches of the medial and lateral cords. No scarring was noted in the area, and there was no sign of direct injury to the nerve structures otherwise. The pseudoaneurysm was opened, and laminated blood clot was removed. The pin-hole-sized communication between the pseudoaneurysm and the axillary artery was repaired with a stitch of 6-0 monofilament polypropylene (Fig. 2) in a figure-of-eight fashion. After repair of the pseudoaneurysm, the flow of blood was demonstrated throughout the branches of the brachial artery.

Four months after the most recent operation, examination showed no apparent recovery of function of the median nerve.

### Discussion

There are many modifications of regional block anesthesia of the brachial plexus<sup>2,4,10</sup>. The axillary-paresthesia technique is performed with an exploratory needle placed anterior and posterior to the axillary artery. Paresthesia is sought before each injection of local anesthesia<sup>1</sup>. With the perivascular technique, a local anesthetic is injected anterior and posterior to the artery after localization of the sheath by the characteristic oscillations of the needle from the pulsations of the artery<sup>7</sup>. The transarterial method involves temporary penetration of the axillary artery with the needle to confirm its location within the sheath<sup>3</sup>.

The angle at which the exploratory needle entered the artery in our patient is unknown, but it could have been a factor in lacerating rather than in puncturing the wall of the vessel. The size of the needle and the volume of anesthetic solution have been described as safe and effective<sup>3</sup>.

When used for access, the axillary artery may be damaged during arteriography<sup>5,9</sup>. The localized hematoma or pseudoaneurysm is constrained within the tough axillary sheath and is not free to expand into the surrounding soft tissue. Clinically, it seems that compression that is severe enough to produce motor dysfunction for twenty-four hours could result in wallerian degeneration<sup>9</sup>. Rare instances of a traumatic pseudoaneurysm of the axillary artery that resulted in neuropathy of the brachial plexus have been reported<sup>6</sup>.

Although naproxen does not affect the prothrombin time and platelet count, it prolongs bleeding time and platelet aggregation<sup>8</sup>. These effects are absent ninety-six hours after the last dose. Our patient may have been predisposed to arterial damage because of advanced atherosclerotic peripheral vascular disease, and it would have been prudent to discontinue naproxen four days before the operation.

Axillary block of the brachial plexus has become a popular technique of regional anesthesia for operations on the upper extremity because of its simplicity and its paucity of complications. Neurological recovery after compression of the brachial plexus by a pseudoaneurysm of the axillary artery is poor, and an aggressive approach to diagnosis and treatment is warranted<sup>6</sup>.

### References

1. ACCARDO, N. J., and ADRIANI, JOHN: Brachial Plexus Block: A Simplified Technic Using the Axillary Route. *Southern Med. J.*, **42**: 920-923, 1949.
2. BONICA, J. J.; MOORE, D. C.; and ORLOV, MORTON: Brachial Plexus Block Anesthesia. *Am. J. Surg.*, **78**: 65-79, 1949.
3. DE JONG, R. H.: Axillary Block of the Brachial Plexus. *Anesthesiology*, **22**: 215-225, 1961.
4. DE PABLO, J. S., and DIEZ-MALLO, J.: Experience with Three Thousand Cases of Brachial Plexus Block; Its Dangers. Report of a Fatal Case. *Ann. Surg.*, **128**: 956-963, 1948.
5. DUDRICK, S.; MASLAND, W.; and MISHKIN, M.: Brachial Plexus Injury following Axillary Artery Puncture. Further Comments on Management. *Radiology*, **88**: 271-273, 1967.
6. GALLEN, JOHN; WISS, D. A.; CANTELMO, NANCY; and MENZOIN, J. O.: Traumatic Pseudoaneurysm of the Axillary Artery: Report of Three Cases and Literature Review. *J. Trauma*, **24**: 350-354, 1984.
7. HUDON, F., and JACQUES, A.: Block of the Brachial Plexus by the Axillary Route. *Canadian Anaesth. Soc. J.*, **6**: 400-405, 1959.
8. NADELL, JUDITH; BRUNO, JOHN; VARADY, JOHN; and SEGRE, E. J.: Effect of Naproxen and of Aspirin on Bleeding Time and Platelet Aggregation. *J. Clin. Pharmacol.*, **14**: 176-182, 1974.
9. O'KEEFE, D. M.: Brachial Plexus Injury following Axillary Arteriography. Case Report and Review of the Literature. *J. Neurosurg.*, **53**: 853-857, 1980.
10. WINNIE, A. P.; RADONJIC, RADISA; AKKINENI, S. R.; and DURRANI, ZIA: Factors Influencing Distribution of Local Anesthetic Injected into the Brachial Plexus Sheath. *Anesth. and Analg.*, **58**: 225-234, 1979.